

Surgical management of valsalva retinopathy

Manejo cirúrgico da retinopatia de valsalva

Kim Vieira Kayat¹

1. Departamento de Oftalmologia-Retina, Universidade Federal São Paulo (UNIFESP), São Paulo, SP, Brazil.

Valsalva retinopathy is a pre-retinal hemorrhage caused by the rupture of superficial retinal capillaries due to increased intra-thoracic or intra-abdominal pressure. Extravasated blood typically accumulates below the internal limiting membrane (ILM) but can also be found in the subhyaloid space or vitreous cavity.

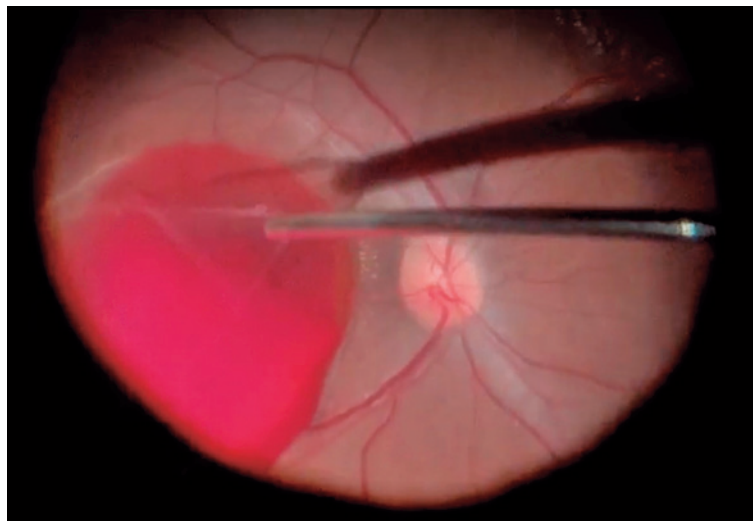
Despite the good visual prognosis in this pathology, the bleeding causes severe visual impairment as it affects the fovea in most cases, and intervention is indicated in cases where early recovery is desired¹.

Treatment can be performed through Nd:YAG laser membranotomy or pars plana vitrectomy (PPV) and ILM peeling with removal of the trapped blood.

In Nd:YAG laser treatment, the posterior hyaloid membrane and ILM are ruptured, allowing the trapped blood to flow into the vitreous cavity clearing

the visual axis. However, this surgical approach aims to directly remove the sub-ILM hemorrhage and the vitreous cavity through VVPP ILM peeling. Despite being more invasive when compared with the YAG laser, this technique allows immediate visual rehabilitation and reduced complications, such as the formation of epiretinal membrane and hemorrhages due to iatrogenic retinal damage^{2,3}.

The present study reports a case of a 50-year-old patient with classic valsalva retinopathy induced by vomiting. The ophthalmological examination revealed a visual acuity of 20/20 in the right eye and hand motion in the left. The retinography and optical coherence tomography findings indicated a large volume of sub-ILM blood, and the chosen surgical approach was PPV associated with ILM peeling.



Keywords: Valsalva retinopathy; Vitrectomy

Corresponding author: Kim Kayat. E-mail: kim_kayat@hotmail.com

Received on: Aug 29, 2023. **Accepted on:** Sept 12, 2023

Funding: No specific financial support was available for this study. **Conflict of interest:** None of the authors have any potential conflict of interest to disclose.

How to cite: Kayat KV. Surgical management of valsalva retinopathy. eOftalmo. 2023;9(3):111-2.

DOI: 10.17545/eOftalmo/2023.00031

 This content is licensed under a Creative Commons Attribution 4.0 International License.

After performing the core vitrectomy, we detached the posterior hyaloid and set the cut-off using a 650mmHg vacuum in a 25G probe. Subsequently, we aspirated the posterior hyaloid around the optic disc, pulled it in the same plane as the retina, and then toward the posterior lens capsule. It is possible to observe the hyaloid detachment wave as it separates from the retina.


Using forceps, we made an opening in the ILM that was already separated (dissected) from the retina by the blood. Considering that the ILM was already detached from the retina, the peeling can be performed using the vitrector probe with active aspiration without any dye or forceps, which is generally necessary for other surgeries to remove this membrane. The advantage of performing the peeling with the probe is that we get a good grasp of the ILM. Furthermore, the blood released after peeling can be aspirated without changing the instrument.

Subsequently, we used a back-flush to lift the residual blood deposited on the macula and then aspirated the blood with a vitrector. Finally, the vitreous base was revised, and balanced salt solution was left as a vitreous substitute.

REFERENCES

1. Rohowetz LJ, Patel V, Sridhar J, Yannuzzi NA. VALSALVA RETINOPATHY: Clinical Features and Treatment Outcomes. *Retina*. 2023 Aug 1;43(8):1317-1320. doi: 10.1097/IAE.0000000000003772. PMID: 36893442.
2. Goel N, Kumar V, Seth A, Raina UK, Ghosh B. Spectral-domain optical coherence tomography following Nd:YAG laser membranotomy in valsalva retinopathy. *Ophthalmic Surg Lasers Imaging*. 2011 May-Jun;42(3):222-8. doi: 10.3928/15428877-20110224-01. Epub 2011 Mar 3. PMID: 21410093.
3. García Fernández M, Navarro JC, Castaño CG. Long-term evolution of Valsalva retinopathy: a case series. *J Med Case Rep*. 2012 Oct 10;6:346. doi: 10.1186/1752-1947-6-346. PMID: 23050866; PMCID: PMC3492032.

AUTHOR INFORMATION



» Kim Kayat

<http://lattes.cnpq.br/6381427776192199>

<https://orcid.org/0000-0002-4114-2449>