

Cerulean cataract: a case report

Catarata cerúlea: relato de caso

Daniele Bravim Longo¹, Larissa de Sá Barreto¹, Tamires Able Carmona¹, Tatiana de Melo Vasconcelos¹

1. Hospital Federal de Bonsucesso, Rio de Janeiro, RJ, Brazil.

KEYWORDS:

Cataract; Ophthalmologic surgical procedures; Congenital abnormalities.

PALAVRAS-CHAVE:

Catarata; Procedimentos cirúrgicos oftalmológicos; Anomalias congênitas.

ABSTRACT

Cerulean cataract is a rare subtype of cataract that is primarily caused by an autosomal dominant gene, which causes low visual acuity in children and adolescents. Herein, we report a patient with a rare type of cataract to raise awareness of its occurrence and allow its prompt diagnosis and more efficient treatment. Cerulean cataract is a rare form of congenital cataract; of them 25% are of hereditary and genetic etiology. Neonates should undergo a proper eye test (red reflex examination) while at the nursery for an early congenital cerulean cataract diagnosis. Presently, several surgical techniques have been described for congenital cataract treatment, considering the challenges faced during the intraoperative period, as it deals with crystallins that are softer than usual. Cerulean cataract has rare occurrence, with 25% being hereditary and needing no treatment, making observation the best course of action. Surgical treatment was recommended in this case to improve the patient's visual acuity and reduce the risks of amblyopia.

RESUMO

A catarata cerúlea é um subtipo raro de catarata congênita, predominantemente associado a um gene autossômico dominante, que pode causar baixa acuidade visual em crianças e adolescentes. O objetivo é relatar o caso clínico de um paciente com um tipo raro de catarata, para divulgar a sua ocorrência, de modo que o seu diagnóstico possa ser feito mais precocemente e o tratamento seja mais eficaz. 25% dos casos de catarata cerúlea são de etiologia hereditária e genética. Para o diagnóstico precoce da catarata cerúlea congênita, é importante que o recém-nascido seja submetido a um exame ocular adequado (teste do reflexo vermelho) ainda no berçário. Atualmente, já foram descritas várias técnicas cirúrgicas para o tratamento de cataratas congênitas, considerando os desafios enfrentados durante a cirurgia, uma vez que estão sendo operados cristalinos mais moles que o habitual. A ocorrência deste tipo de catarata é rara; 25% dos casos são hereditários e não necessitam de tratamento, sendo a observação a melhor conduta. No caso em questão, foi recomendado o tratamento cirúrgico para melhorar a acuidade visual do paciente e reduzir o risco de ambliopia.

INTRODUCTION

Cerulean cataract is a rare subtype of cataract that causes low visual acuity in children and adolescents¹. Low visual acuity does not significantly occur before the age of 2 years; thus, patients are usually asymptomatic during early childhood¹⁻⁴. However, opacities

may grow and cause lost red reflexes and decreased vision in both eyes because both child and crystallin evolve; thus, parents often seek ophthalmological care.

Herein, we report a patient with a rare type of cataract to raise awareness of its occurrence and allow prompt diagnosis and more efficient treatment.

Corresponding author: Daniele Bravim Longo. E-mail: danii-longo@hotmail.com

Received on: Oct 31, 2022. **Accepted on:** Mar 25, 2023.

Funding: No specific financial support was available for this study. **Conflict of interest:** None of the authors have any potential conflict of interest to disclose.

How to cite: Longo DB, Barreto LS, Carmona TA, Vasconcelos TM. Cerulean cataract: a case report. eOftalmo. 2023;9(2):64-6.

DOI: 10.17545/eOftalmo/2023.0019



This content is licensed under a Creative Commons Attribution 4.0 International License.

Ophthalmic examination of the patient, including examination under cycloplegia, biomicroscopy of the anterior segment, retinography, and ocular ultrasound, were documented through their medical record and additional tests.

CASE REPORT

J.B.R. is a 9-year-old boy from Rio de Janeiro who came to our clinic with complaints of progressive loss of visual acuity in both eyes. He reported a family history of congenital cataracts (mother and uncle). The corrected visual acuity was 20/50 in the right eye and 20/80 in the left eye, and the pinhole visual acuity potential was 20/30 in both eyes. The biomicroscopy of the anterior segment showed bluish, punctate, and scattered opacities in the adult, fetal, and embryonic nuclear regions of the crystalline, respectively, in both eyes (Figure 1). Optical coherence tomography of the anterior chamber (Figure 2) was conducted, which revealed no abnormality.

DISCUSSION

Several scholars linked some genes, such as nucleotide 12 deletion associated with the lens β B12 gene and γ -crystalline pseudogene activation; however, out of all the genes studied in animals, only CRYBB2 was highly expressed in the lens of adults⁵. Harder particles that once could not be aspirated can now be easily broken down by this device with the advent of phacoemulsification techniques. Among the most common complications is posterior capsule opacification.

Cerulean cataract has a rare occurrence, and 25% of them are hereditary and need no treatment, making observation the best course of action. In this case, surgical treatment was recommended to improve the patient's visual acuity and reduce the risks of amblyopia.

REFERENCES

1. Stival LRS, Bittar RHG, Lago AM, Nassaralla Junior JJ. Catarata em árvore de Natal. *Rev Bras Oftalmol*. 2015;74(5):309-11.

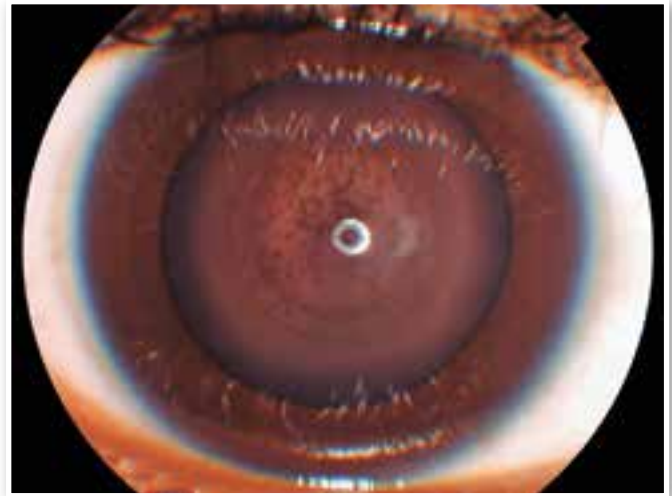

Figure 1. Anterior segment biomicroscopy showing bluish-white opacities in the lens region.

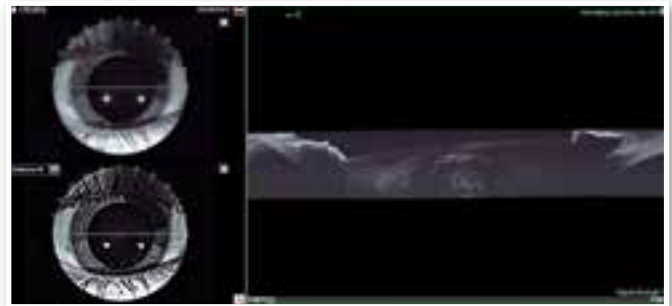


Figure 2. Anterior chamber optical coherence tomography showing the lens with its central opacities.

- Litt M, Carrero-Valenzuela R, LaMorticella DM, Schultz DW, Mitchell TN, Kramer P, et al. Autosomal dominant cerulean cataract is associated with a chain termination mutation in the human beta-crystallin gene CRYBB2. *Hum Mol Genet*. 1997;6(5):665-8.
- Chambers C, Russell P. Deletion mutation in an eye lens beta-crystallin. An animal model for inherited cataracts. *J Biol Chem*. 1991;266(11):6742-6.
- J Ram, A Singh. Cerulean cataract. *QJM*. 2019;112(9):699.
- Shun-Shin GA, Vrensen GF, Brown NP, Willekens B, Smeets MH, Bron AJ. Morphologic characteristics and chemical composition of Christmas tree cataract. *Invest Ophthalmol Vis Sci*. 1993;34(13):3489-96.

AUTHOR'S INFORMATION



» **Daniele Bravim Longo**
<https://orcid.org/0000-0002-4524-2738>
<https://lattes.cnpq.br/1103619903841950>



» **Larissa de Sá Barreto**
<https://orcid.org/0000-0003-2123-5549>
<http://lattes.cnpq.br/9180042334683021>



» **Tamires Able Carmona**
<https://orcid.org/0000-0002-8413-0739>
<http://lattes.cnpq.br/3805694609483739>



» **Tatiana Vasconcelos**
<https://orcid.org/0009-0004-7563-9172>
<https://lattes.cnpq.br/125552307841817>